



Mohamed Abdallah Ould Hamed* and Mouzari Yassine

Departement of Ophtalmology, Med V Military Hospital of Rabat, Morocco

Received: 27 April, 2018

Accepted: 21 May, 2018

Published: 22 May, 2018

*Corresponding author: Mohamed Abdallah Ould Hamed, Department of Ophtalmology, Med V Military Hospital of Rabat, Morocco, Tel: +212655835932, E-mail: badahick@gmail.com

Keywords: Cataract; Lamellar cataract; Zonular cataract; Embryology

<https://www.peertechz.com>

Clinical Image

Congenital unilateral lamellar cataract

Abstract

Lamellar or zonular cataract is a hereditary cataract that is transmitted in an autosomal dominant mode. The crystalline opacities are located at the level of the primary fibers in the embryonic nucleus. This cataract is usually bilateral and asymmetrical. Sometimes the whole nucleus can be affected causing a significant decrease in visual acuity. We report the case of a 19-year-old patient who was consulting for a decrease in visual acuity. Ophthalmic examination revealed unilateral lamellar cataract.

Manuscript

Lamellar or zonular cataract is a hereditary cataract that has a variable phenotype. It is transmitted in an autosomal dominant mode [1,2]. The crystalline opacities are fine and dispersed and are located at the level of the primary fibers in the embryonic nucleus [2]. This cataract is usually bilateral and asymmetrical. Sometimes the whole nucleus can be affected causing a significant decrease in visual acuity [1].

We report the case of a 19-year-old patient who was consulting for a decrease in visual acuity. The patient had no notable pathological history. His visual acuity at Snellen chart was 4/10 in the right eye and 10/10 in the left eye. The slit lamp revealed a lamellar cataract on the right eye (Figure 1). The fundus was no particularity. The patient underwent cataract surgery with an intraocular implant. The operative follow-up was uneventful and the visual acuity has improved to 10/10.

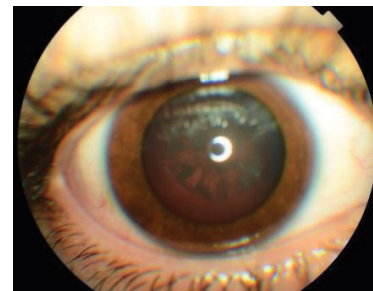


Figure 1: Right eye: lamellar cataract.

References

1. Bu L, Jin Y, Shi Y, Chu R, Ban A, et al. (2002) Mutant DNA-binding domain of HSF4 is associated with autosomal dominant lamellar and Marnier cataract. *Nat Genet* 31: 276-278. [Link: https://goo.gl/p9KW5J](https://goo.gl/p9KW5J)
2. Patil B, Sharma R, Nayak B, Sinha G, Khokhar S (2015) Pediatric cataract. *Delhi J Ophthalmol* 25: 160-165. [Link: https://goo.gl/c1sfQd](https://goo.gl/c1sfQd)